ABSTRACTS SELECTED FOR POSTER PRESENTATIONS

Hepatobiliary Cancer

abstr 0937

Intraluminal Brachytherapy as a Palliative Treatment for Inoperable Klatskin Tumor: Case Report

A. Chauhan[1], P.U. Saxena[2], S. Charudutt[3]

[1]Medical Student, Kasturba Medical College
[2]Assistant Professor, Department of Radiation Oncology, Kasturba Hospital
[3]Assistant Professor, Department of Radiodiagnosis, Kasturba Hospital
Manipal, India

Background: Klatskin tumor, also known as hilar cholangiocarcinoma, occurs at the junction of the right and left hepatic bile ducts. These tumors are usually not resectable at the time of presentation. Stenting and catheterization are common palliative measures used to relieve obstruction. Recently, intraluminal brachytherapy (ILBT) has been tried as a palliative treatment modality to relieve intraluminal bile duct obstruction. We report a case of a patient with inoperable hilar cholangiocarcinoma who underwent biliary stenting, followed by intraluminal brachytherapy (ILBT) as a palliative approach.

Methods: ILBT was attempted in a Klatskin tumor that had earlier failed multiple attempts of percutaneous biliary drainage due to tube blocking. High dose rate (HDR) brachytherapy (source, iridium-192) was given using a remote afterloader (Nucletron Microselectron) to deliver 30 Gy of radiation in 3 days.

Result: Computed tomography scans at 6 months and 2 years after ILBT show no evidence of tumor and a patent biliary system.

Conclusion: Remote afterloading brachytherapy systems can be used at the time of biliary stenting to ensure prolonged patency of the ducts, with excellent palliative outcome in cases of inoperable biliary tumor.

International Society of Gastrointestinal Oncology
2009 Gastrointestinal Oncology Conference
October 1–3, 2009

ABSTRACTS SELECTED FOR POSTER PRESENTATIONS

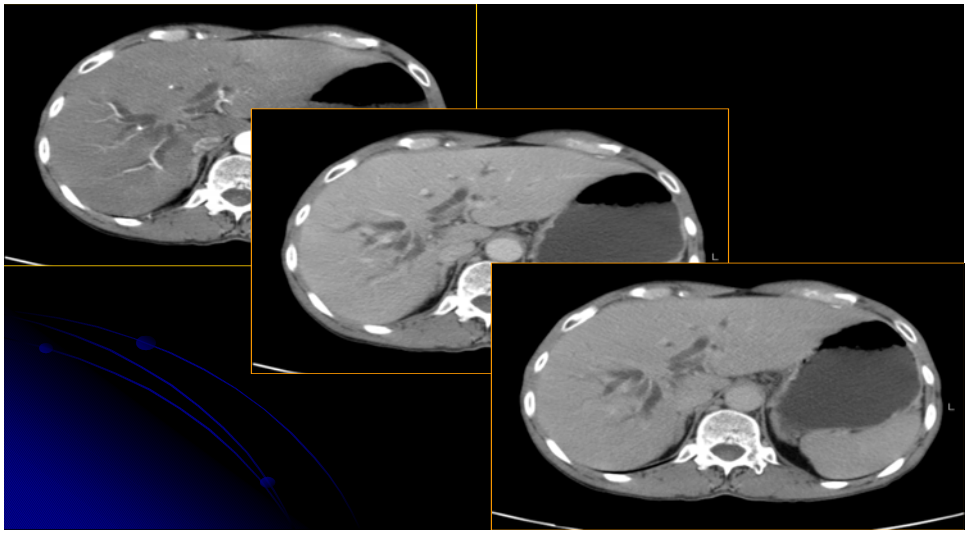

CT Scan Patient with Klatskin Tumor

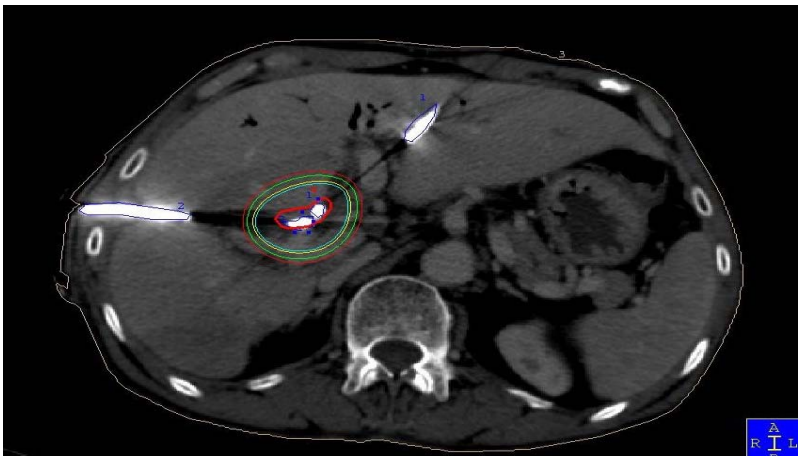

TRANSVERSE SECTION SHOWING THE ISODOSE

DISTRIBUTION AROUND THE TUMOR